

Practice Advisor

Clinical Casebook AcuPulse Treatments

Worldwide collection of before and after images



PB-1002909 Rev D

Practice Advisor AcuPulse Treatments

Images of typical treatment results, with the AcuPulse system

Indications depicted include:

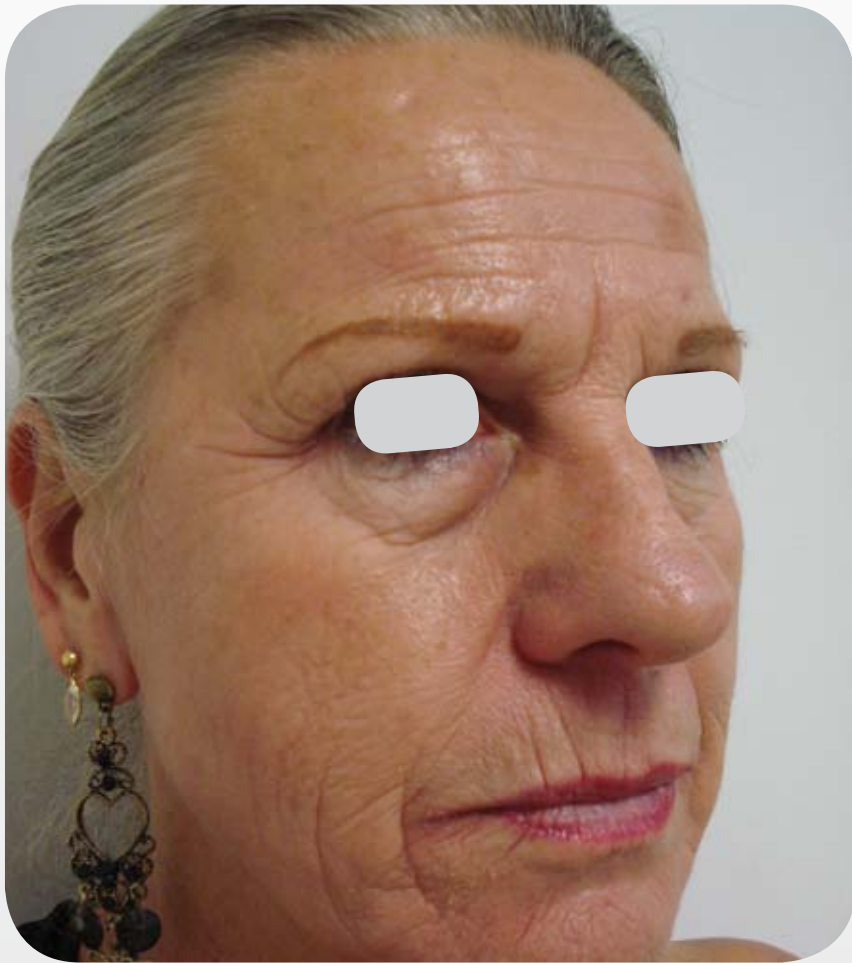- Acne scars
- Surgical scars
- Fractional ablative resurfacing
- Deep wrinkles
- Blepharoplasty
- Skin tags
- Syringomas

Warnings and risks

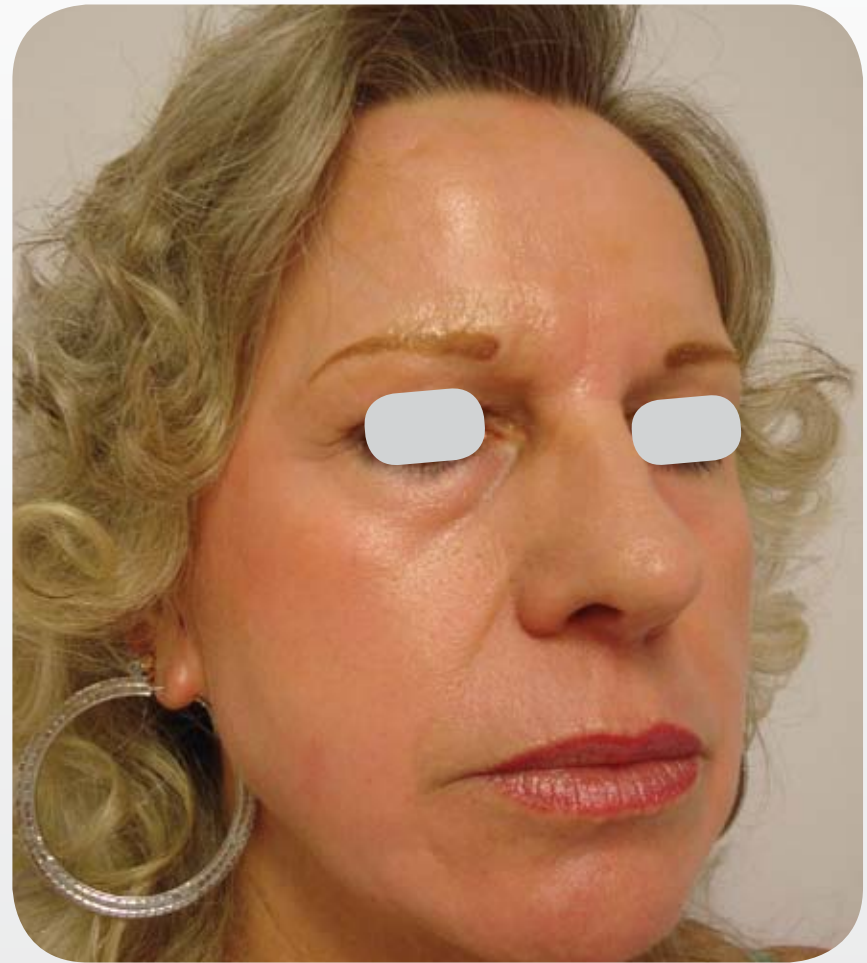Lumenis CO₂ laser procedures are not suitable for everyone, for example patients who have taken Accutane (Isotretinoin) within the past 6-12 months, or had a history of keloid formation. Risks may include change of pigmentation, infection, redness or textural changes. Be sure to consult your physician regarding treatment options available and related contraindications and risks based on your individual concerns and medical history, before choosing a treatment.



Combo™ - for Skin Resurfacing



Baseline

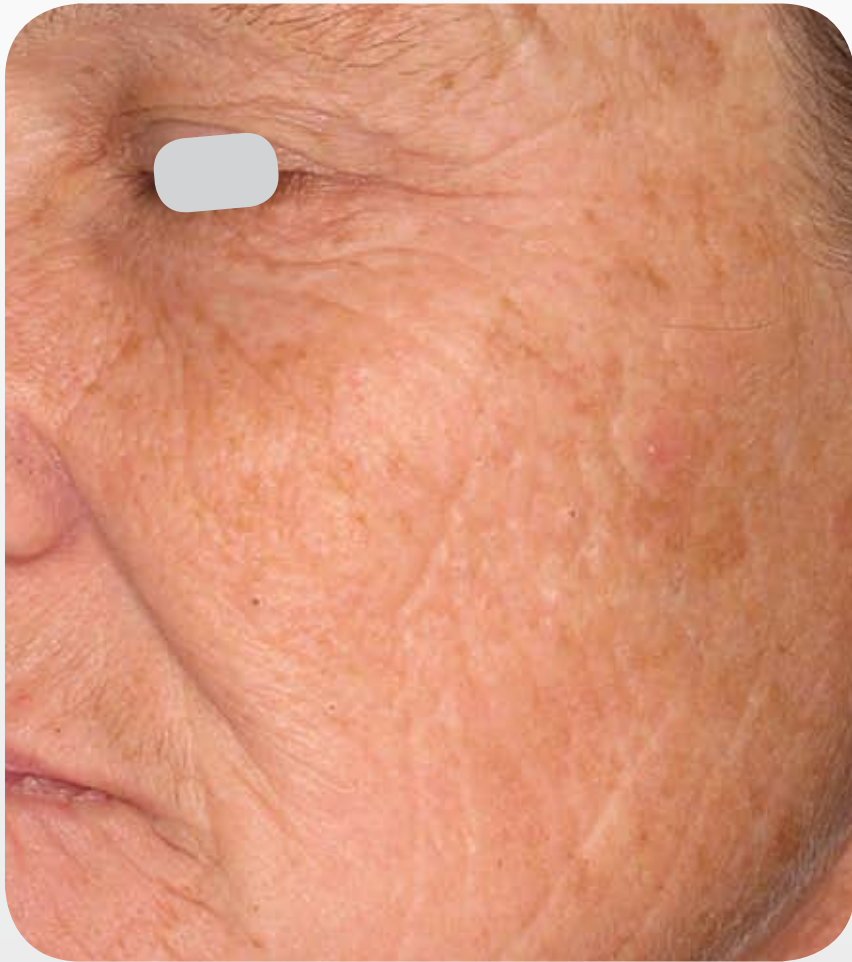

3 months after 1 treatment

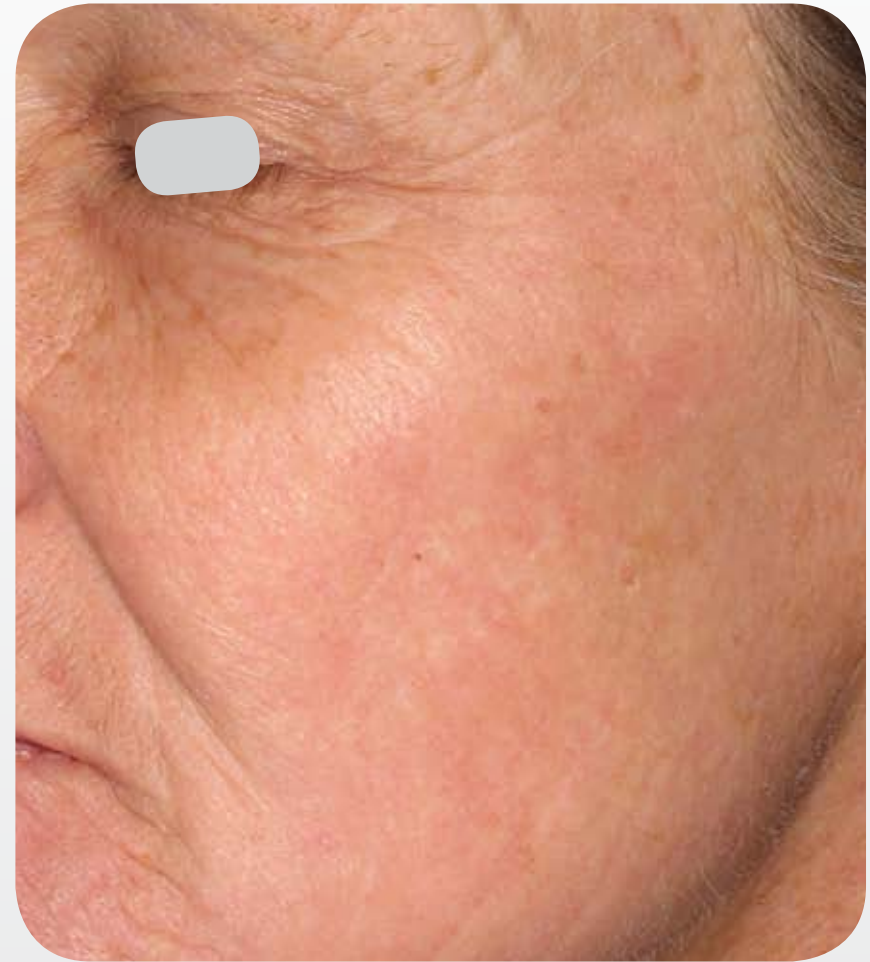Courtesy of Rafael Nunes, MD

PB-1002909 Rev D

Skin Resurfacing

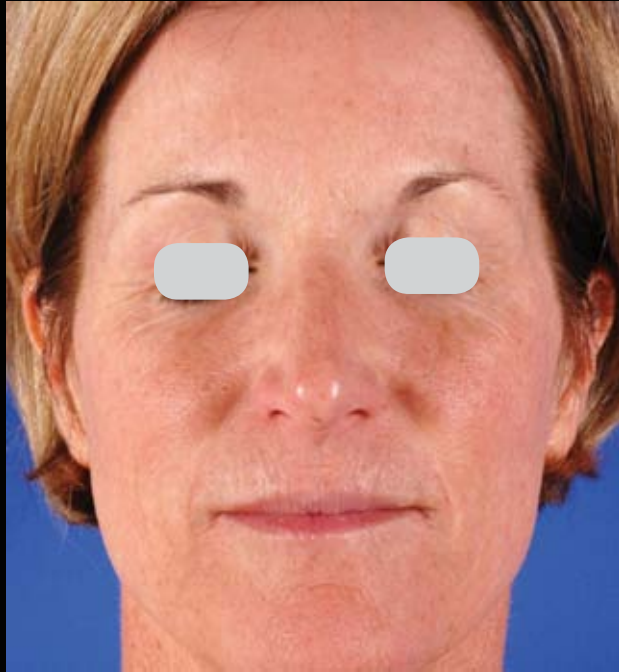


Baseline

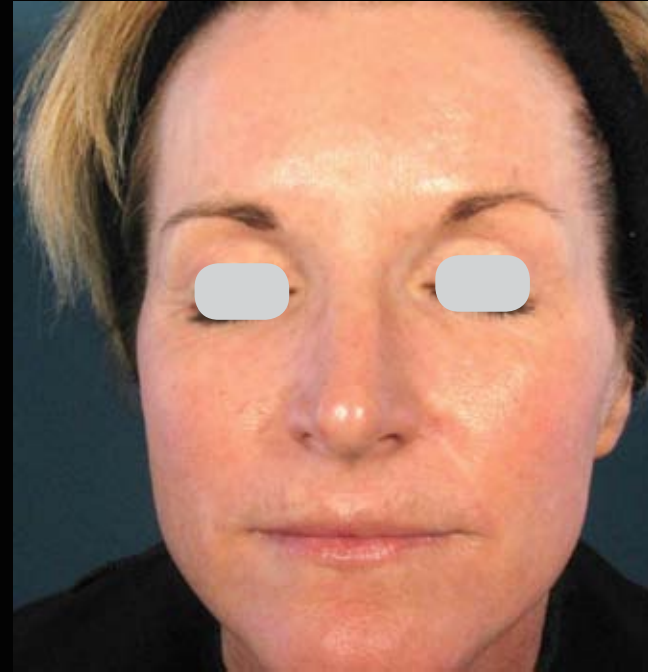

1 month after treatment

Skin Resurfacing



Baseline

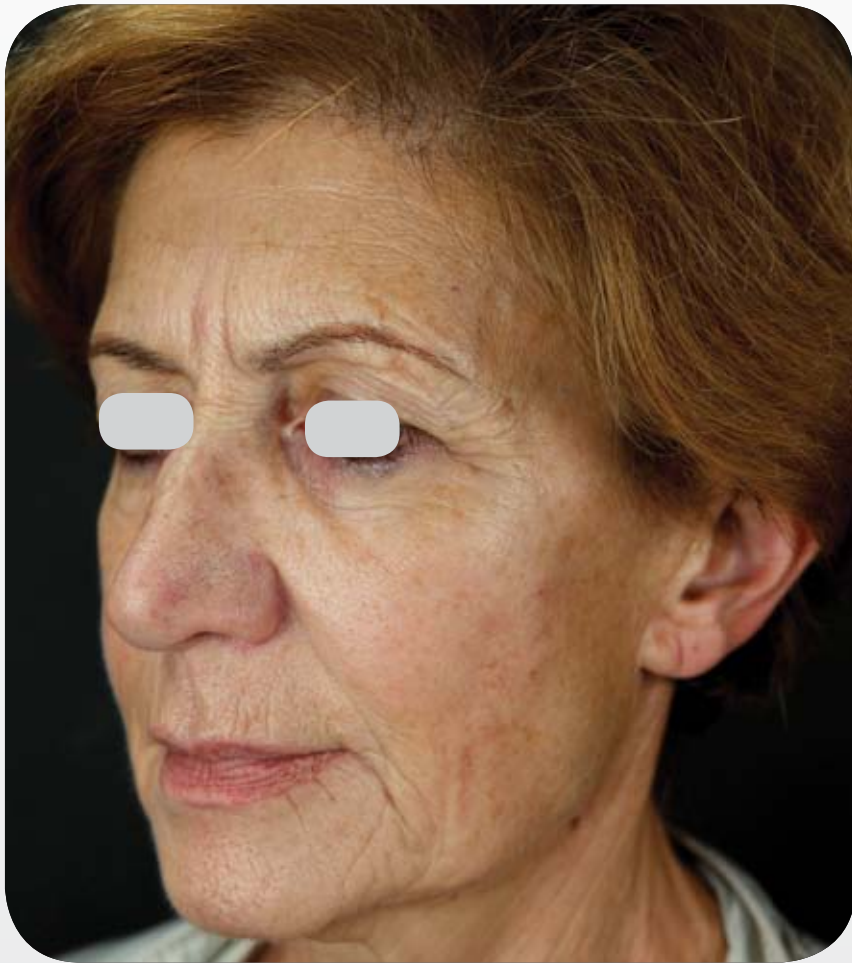


4 months after treatment

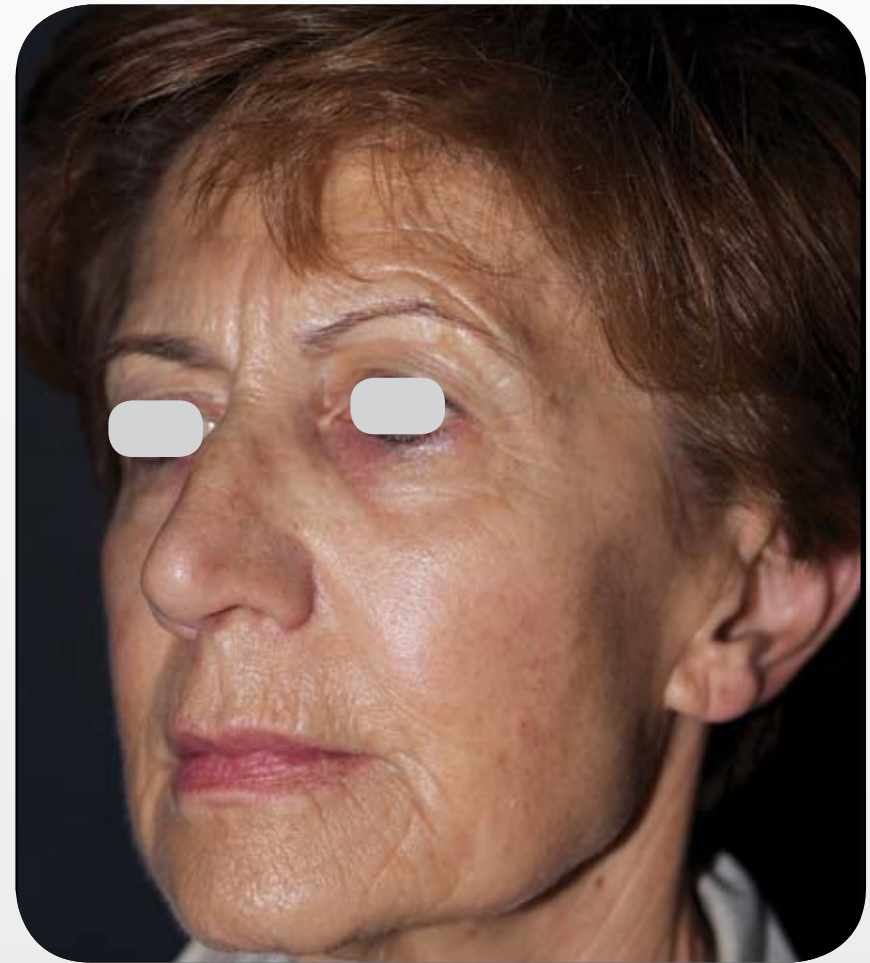Courtesy of Girish Munavalli, MD

PB-1002909 Rev D

Combo™ - for Skin Resurfacing



Baseline

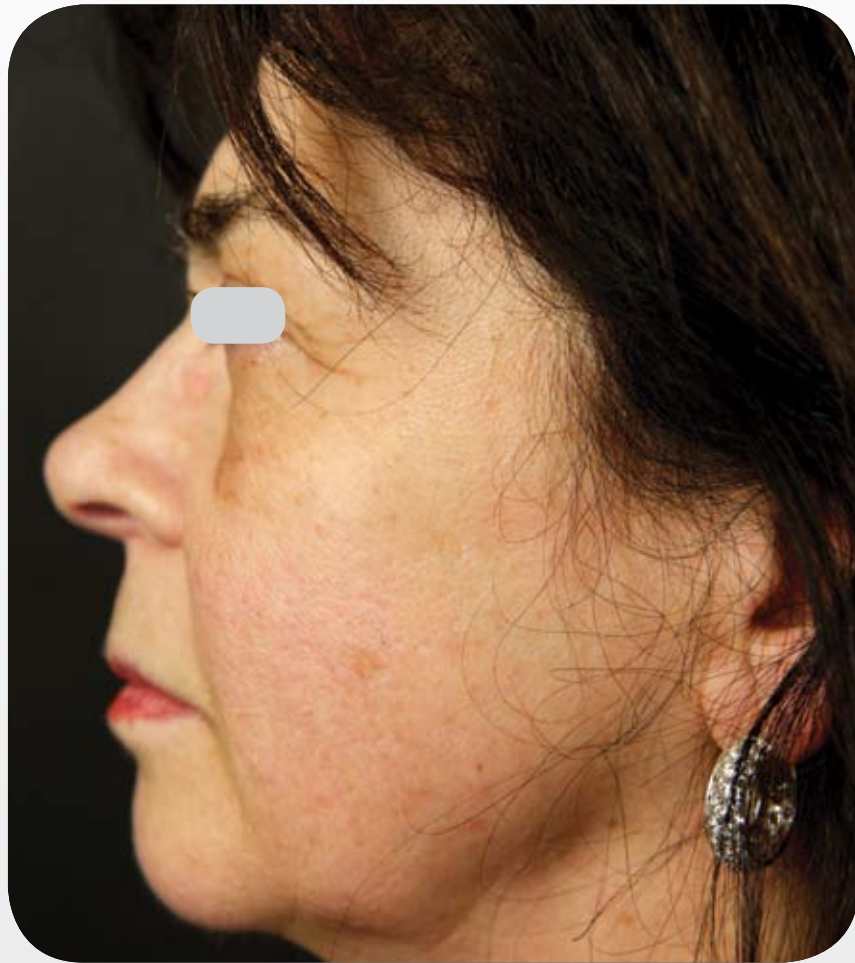

After 1 treatment

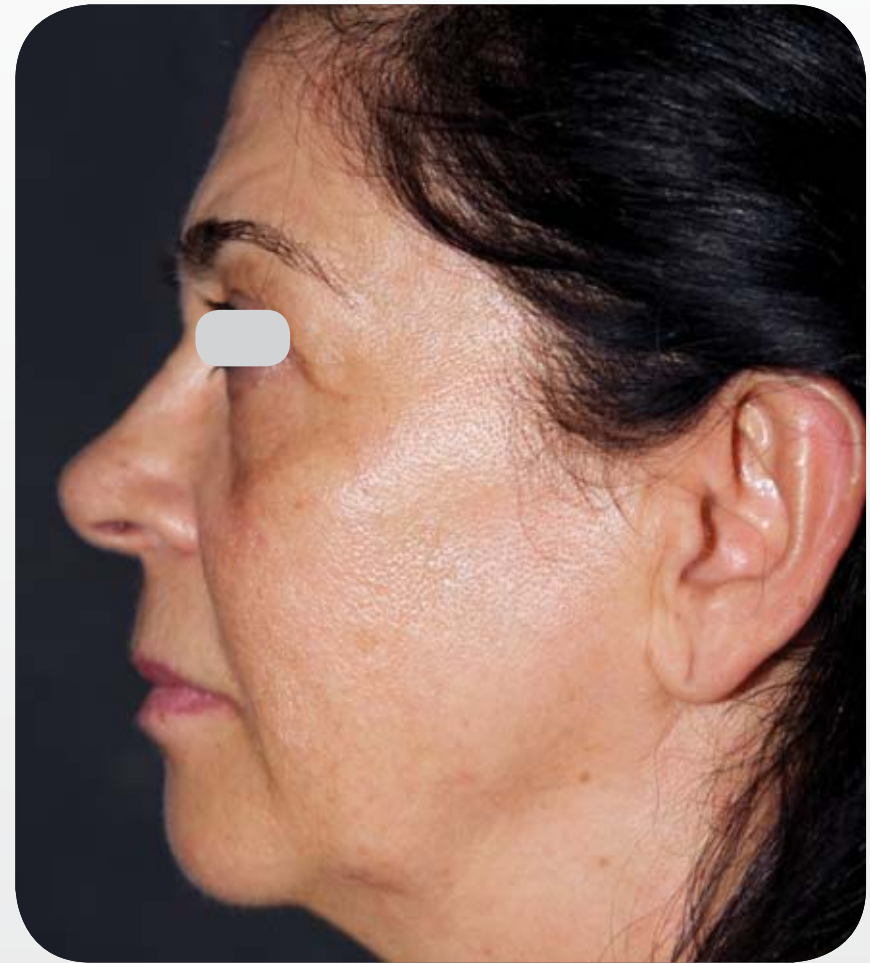Courtesy of Luca Piombino, MD

PB-1002909 Rev D

Combo™ - for Skin Resurfacing



Baseline

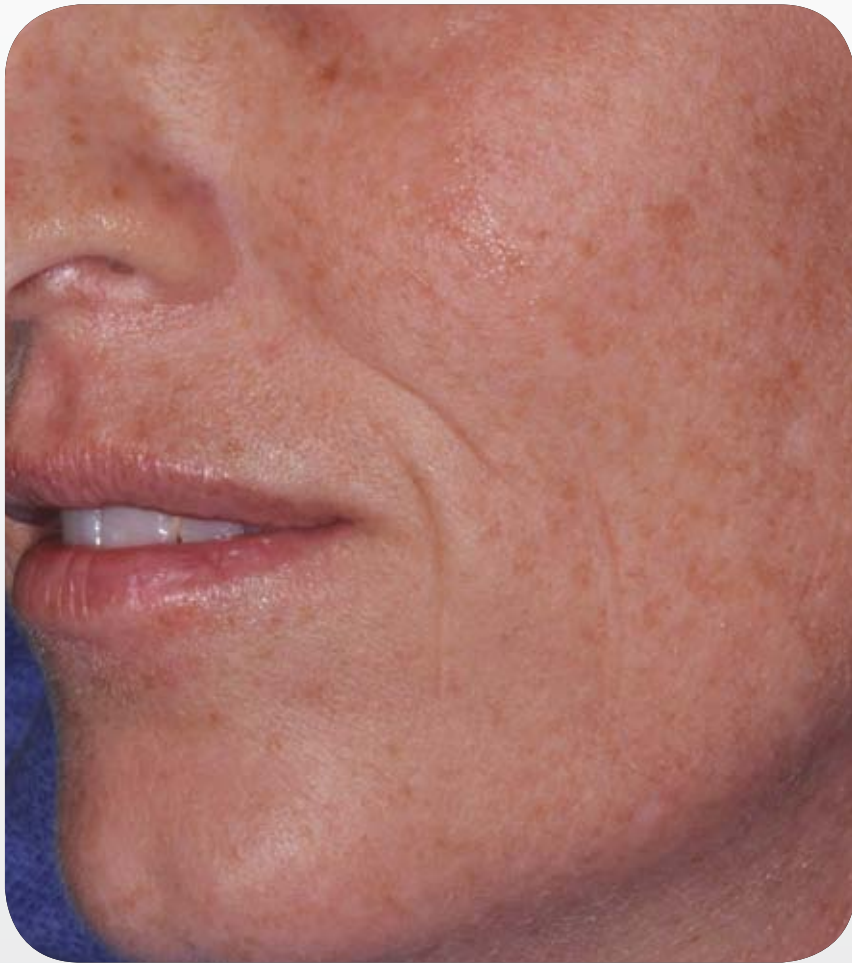

After 1 treatment

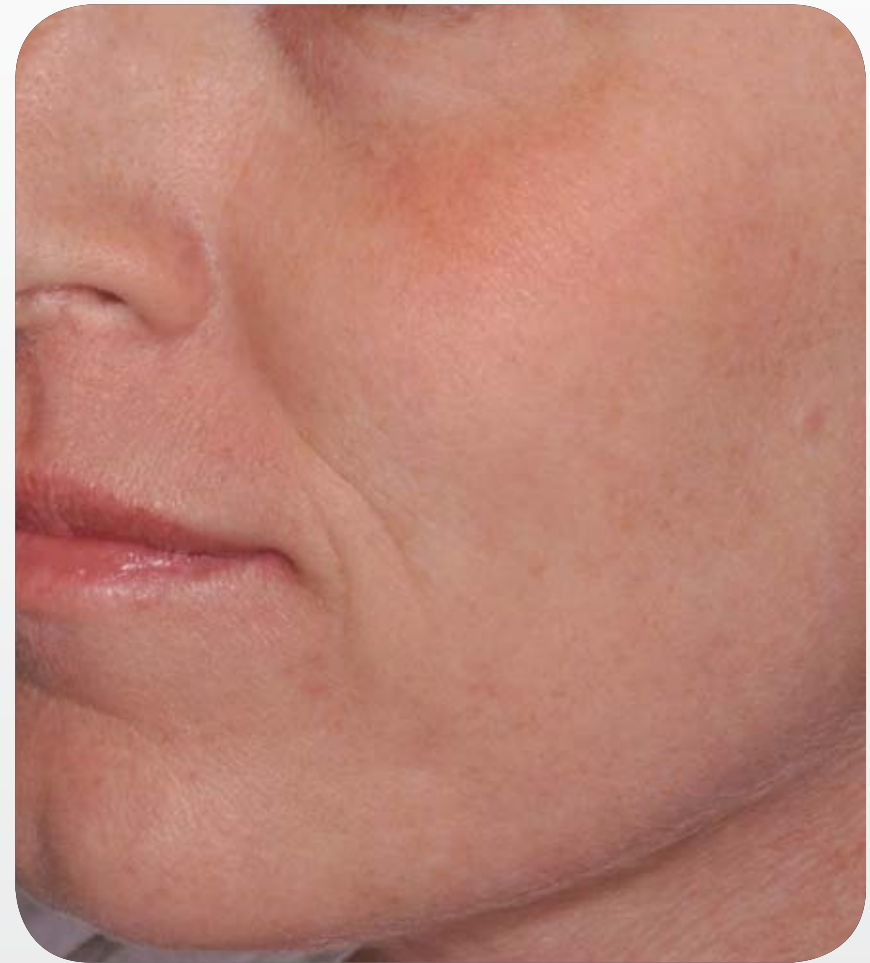Courtesy of Luca Piombino, MD

PB-1002909 Rev D

FeatherTouch™ - for Skin Resurfacing Combined with M22™ IPL for Pigmentation

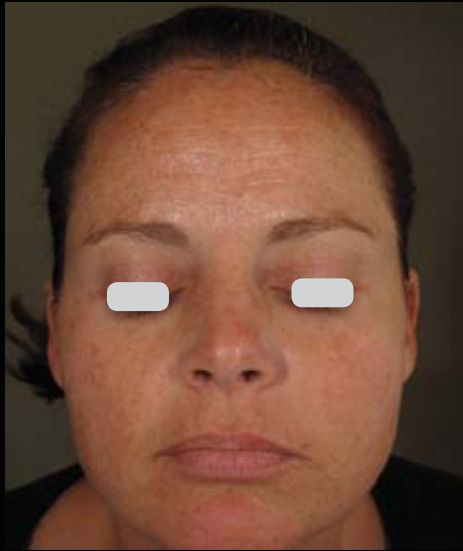

Baseline

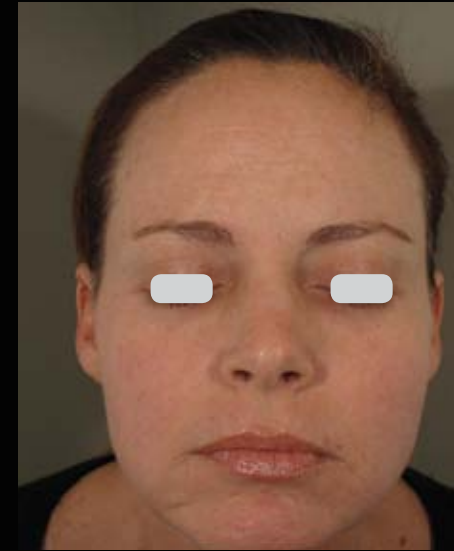

3 months after 1 treatment

Combo™ – for Skin Resurfacing Combined with M22™ IPL for Pigmentation



Baseline

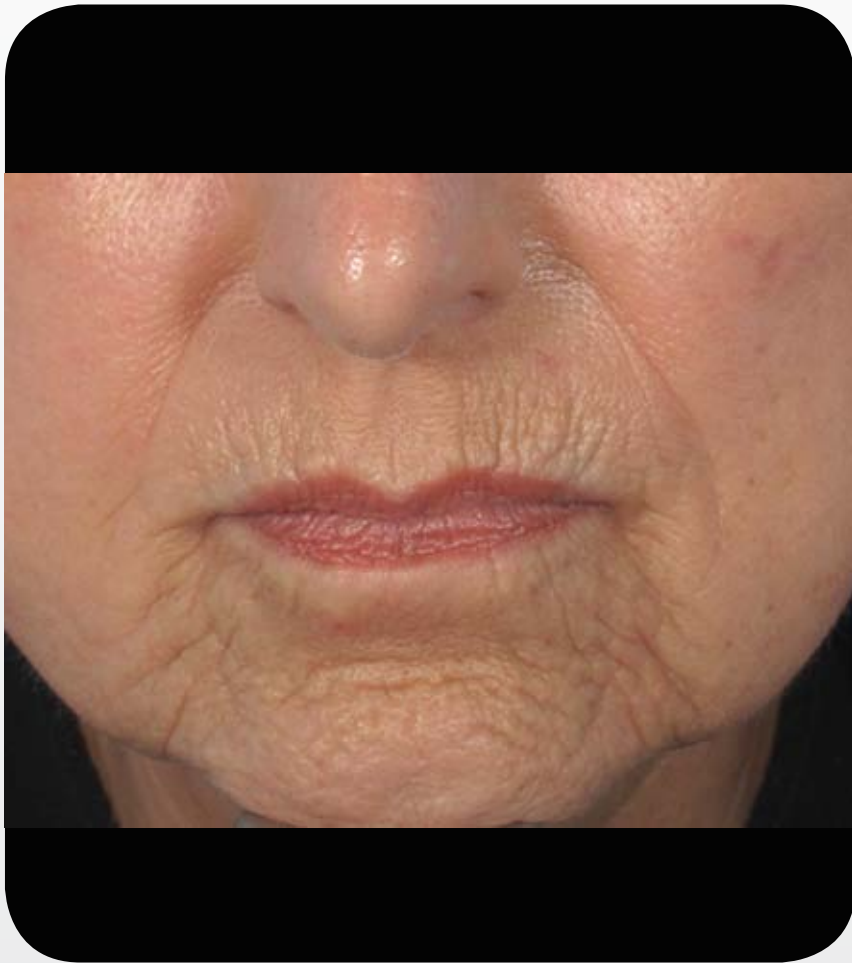

4 months after 1 treatment

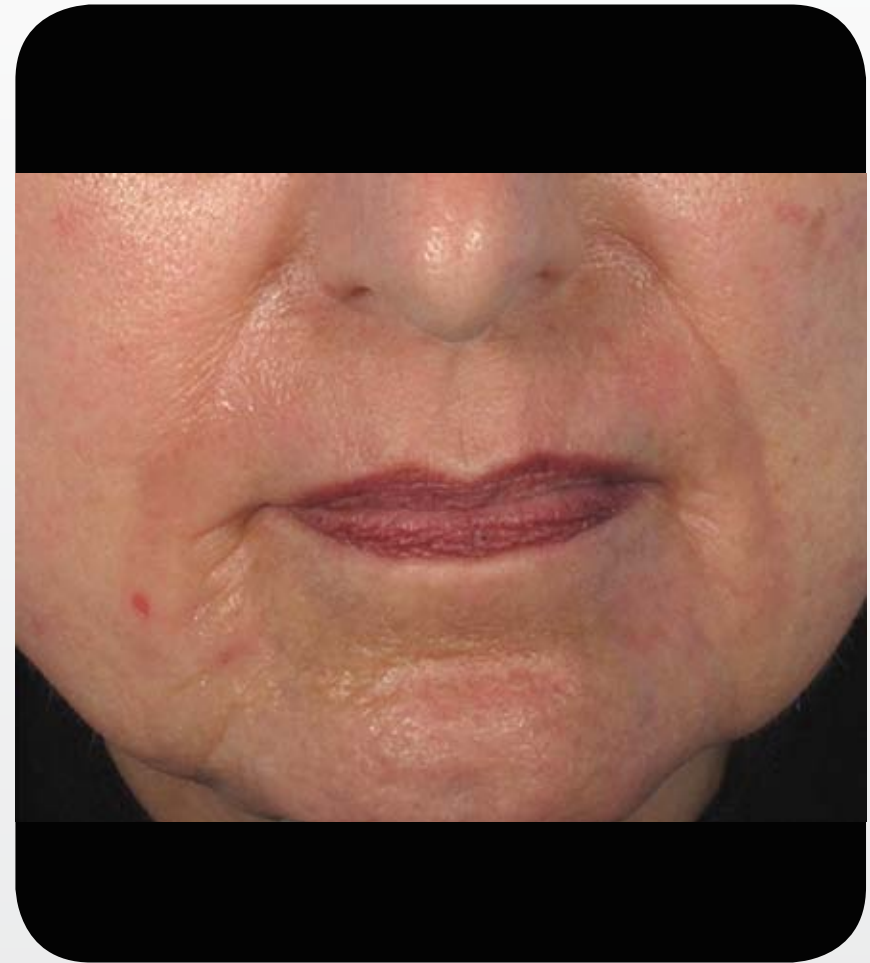Courtesy of Girish Munavalli, MD

PB-1002909 Rev D

Deep™ & Combo™ - for Perioral Rhytides



Baseline

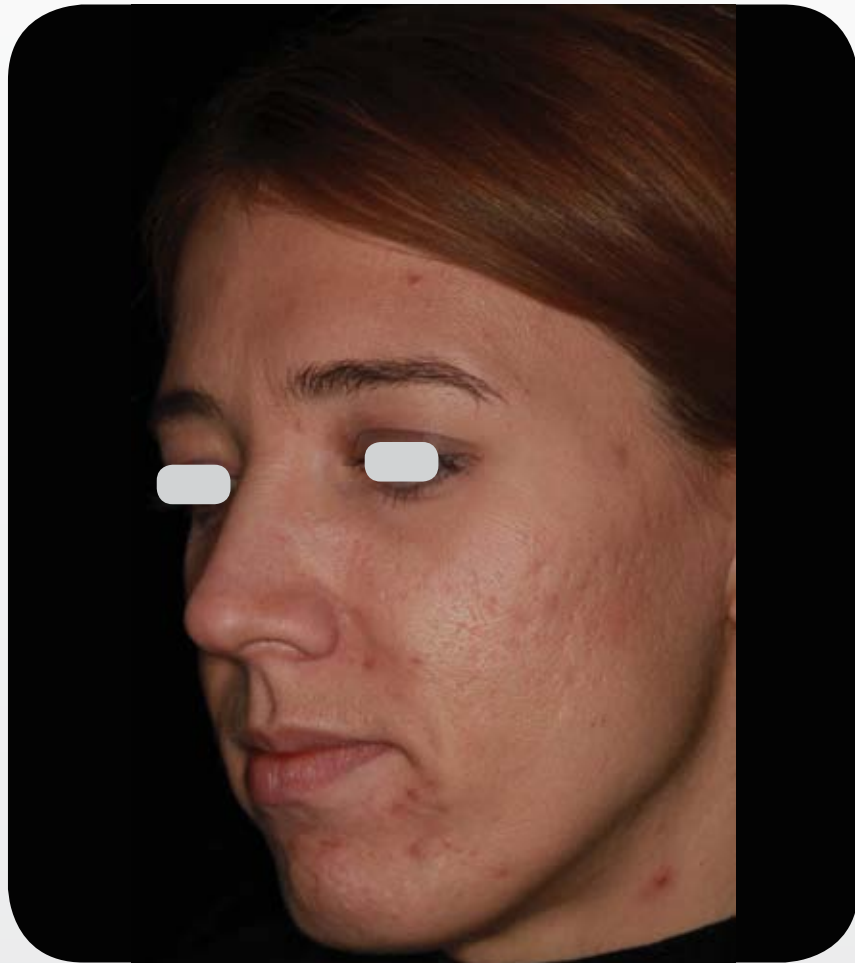


6 months after 1 treatment

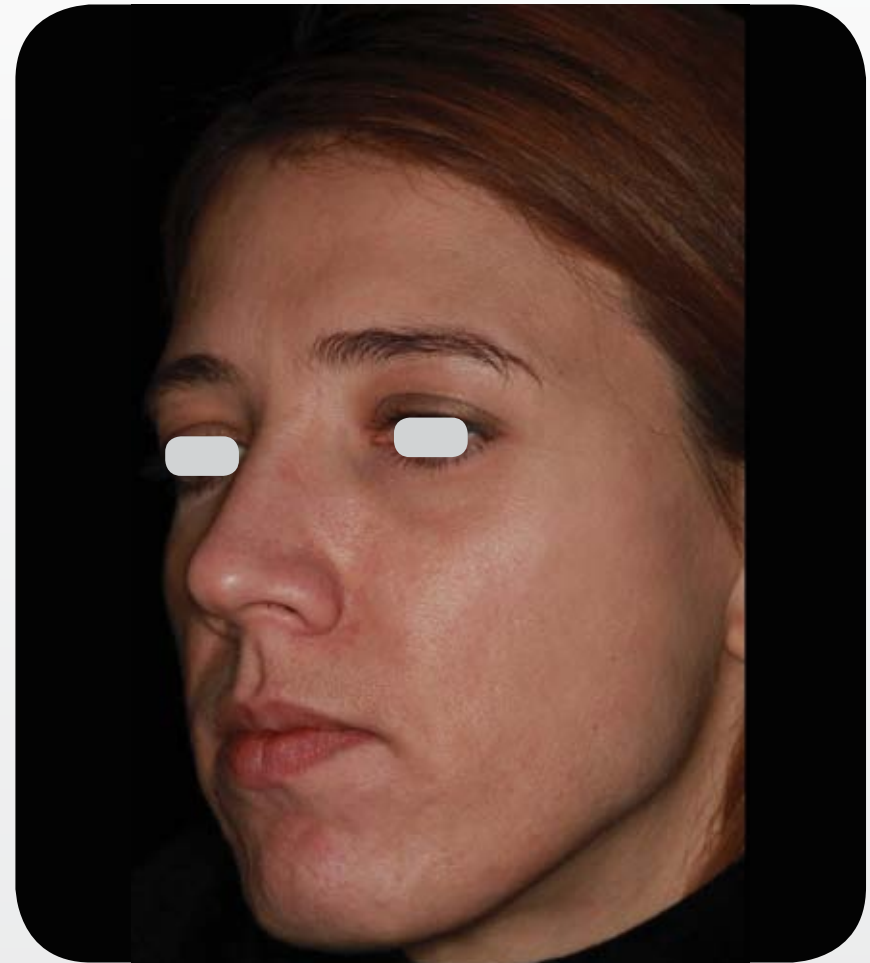Courtesy of Girish Munavalli, MD

PB-1002909 Rev D

Deep™, Combo™ & Superficial™ - for Acne Scars



Baseline

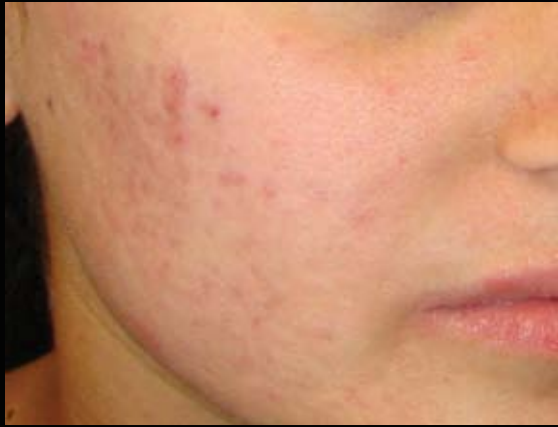

6 months after 1 treatment

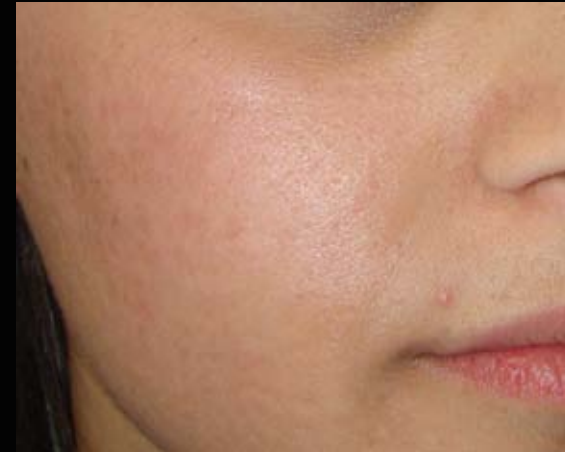Courtesy of Matteo Tretti Clementoni, MD

PB-1002909 Rev D

Combo™ - for Acne Scars



Baseline

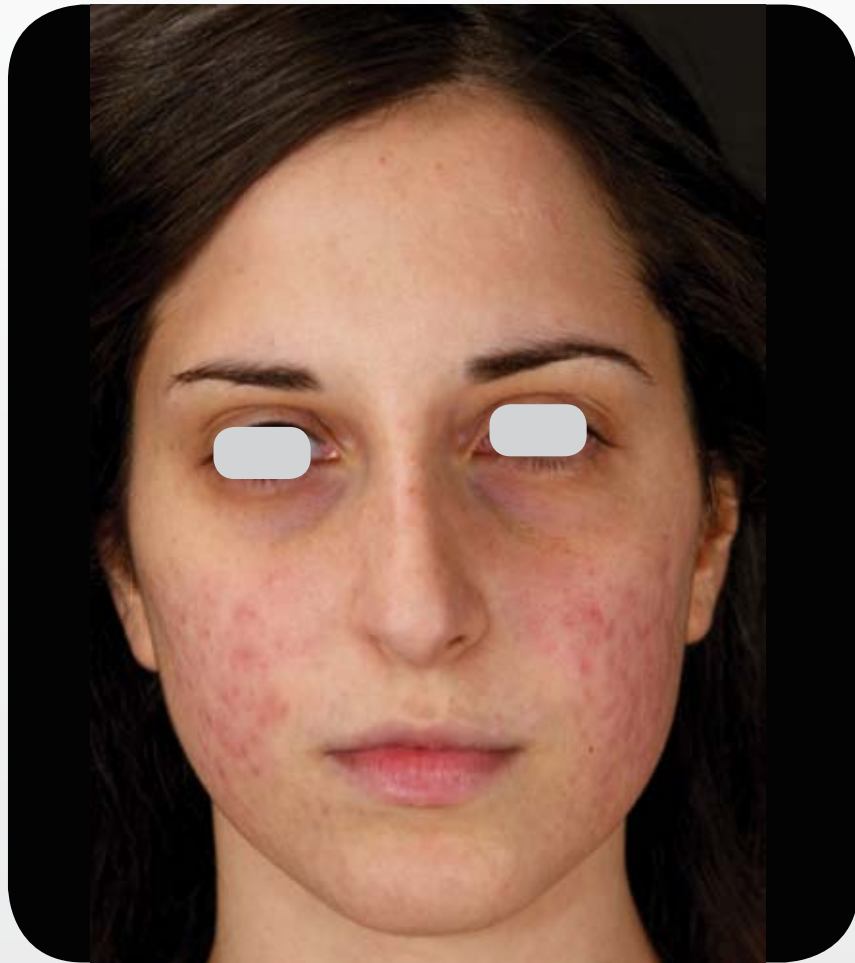


6 months after 1 treatment

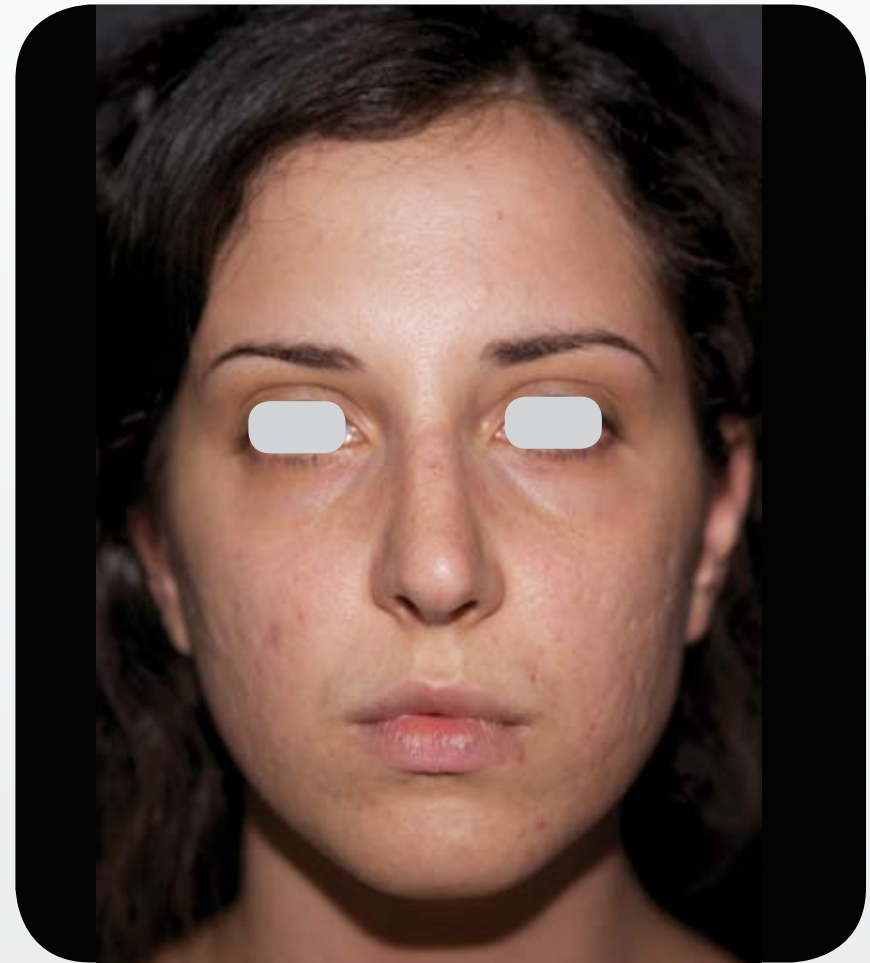
Courtesy of Francesca de Angelis, MD

PB-1002909 Rev D

Combo™ - for Acne Scars



Baseline

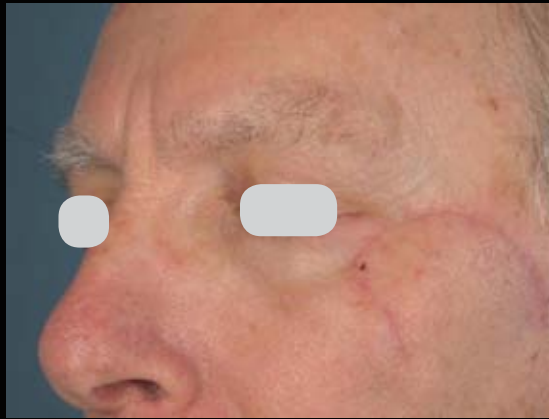

After 1 treatment

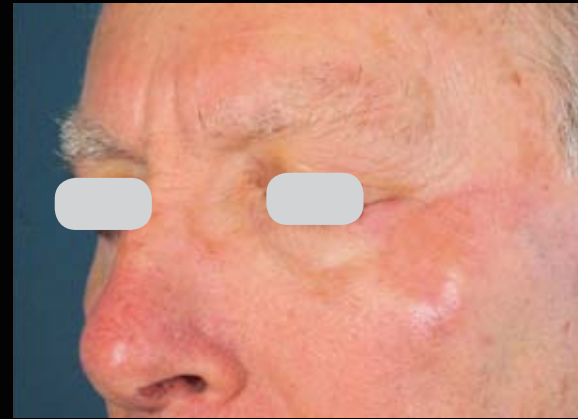
Courtesy of Luca Piombino, MD

PB-1002909 Rev D

Scar Revision



Baseline

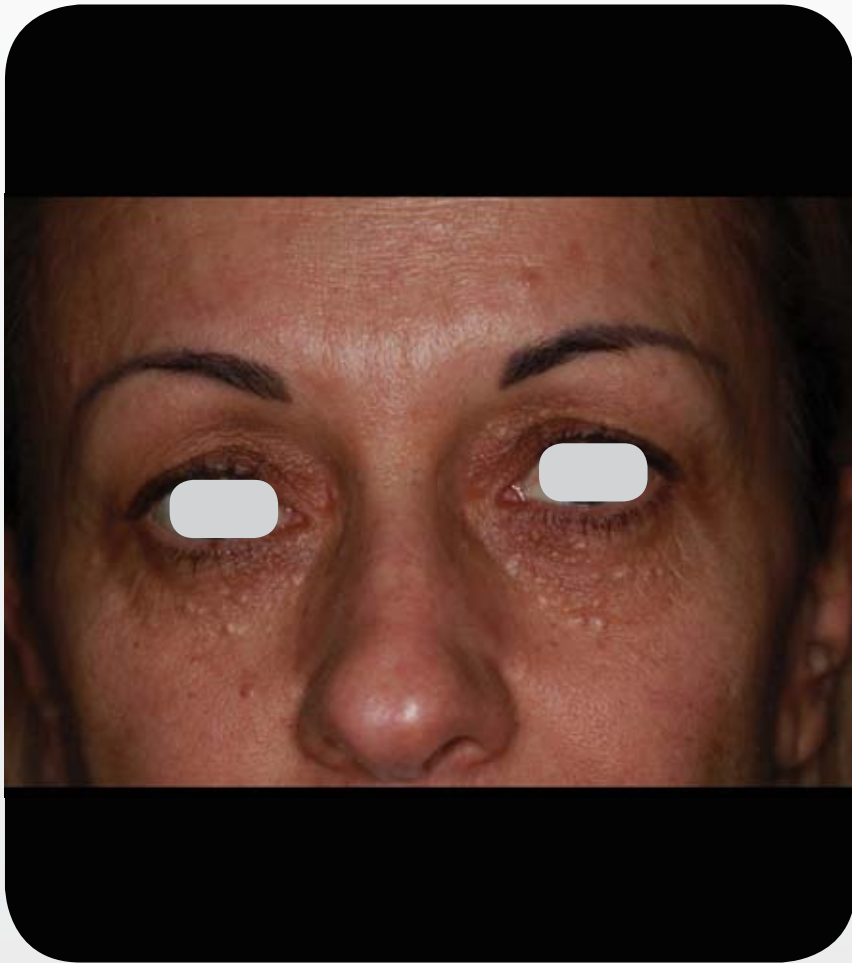


6 months after treatment

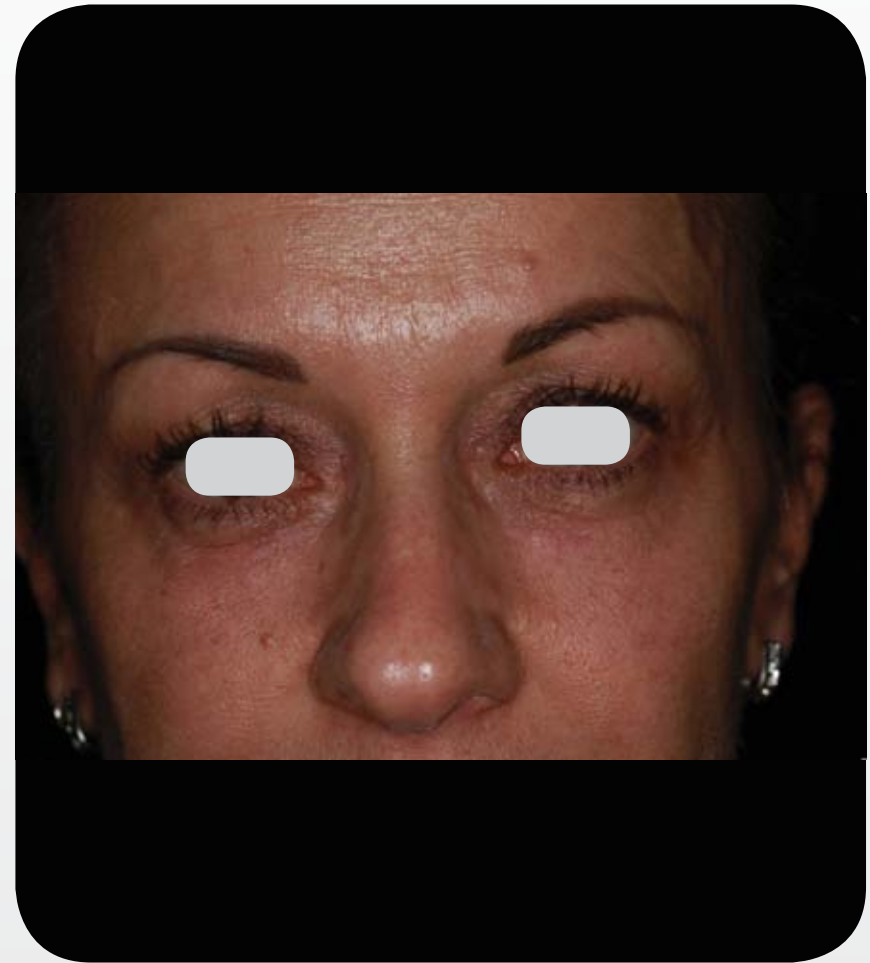Courtesy of Girish Munavalli, MD

PB-1002909 Rev D

FineTouch™ & FeatherTouch™ for Syringomas, Combo™ for Lower Periorbital Resurfacing



Baseline

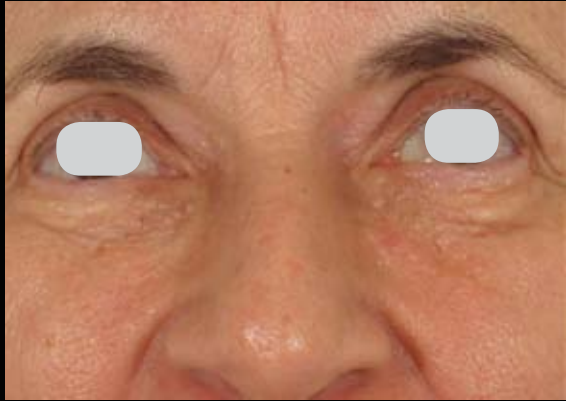

6 months after 1 treatment

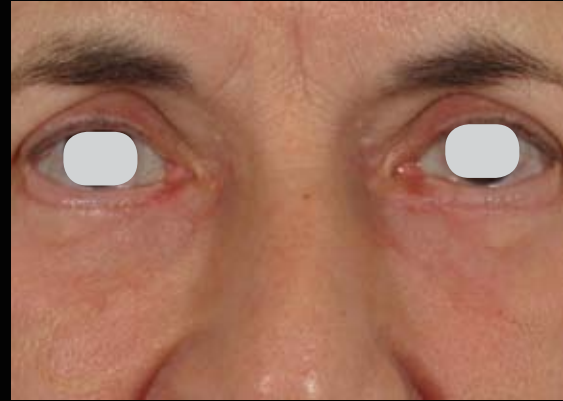Courtesy of Matteo Tretti Clementoni, MD

PB-1002909 Rev D

Bleph™ for Upper & Lower Eyelid Blepharoplasty, FineTouch™ & FeatherTouch™ for Syringomas, Combo™ for Lower Periorbital Resurfacing

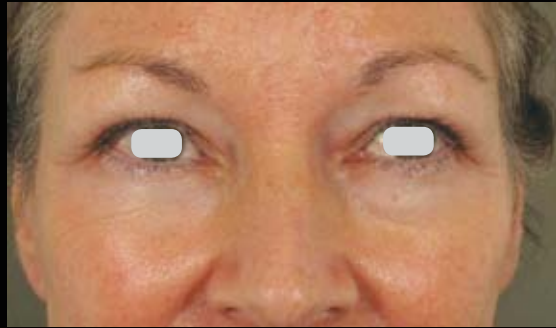

Baseline

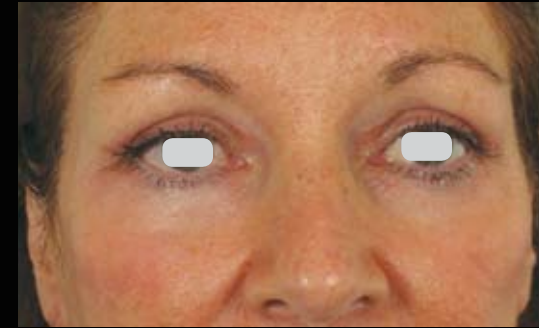

8 weeks after 1 treatment

Bleph™ for Upper & Lower Eyelid Blepharoplasty, Combo™ for Lower Eyelid Resurfacing

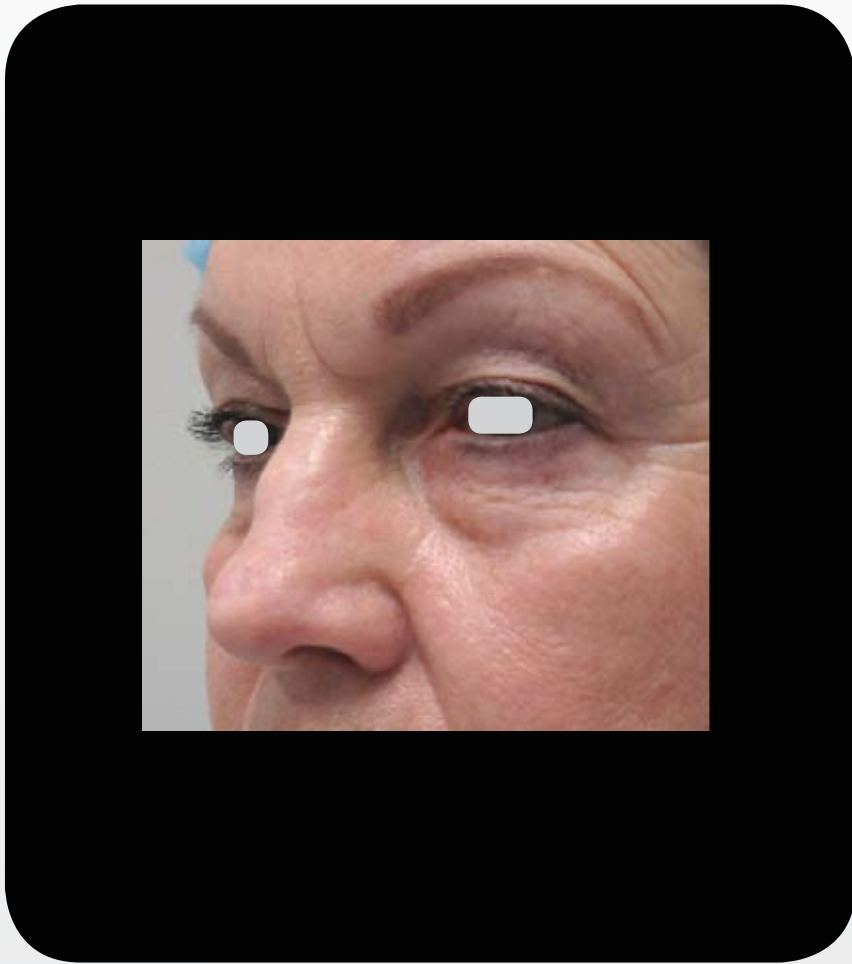


Baseline

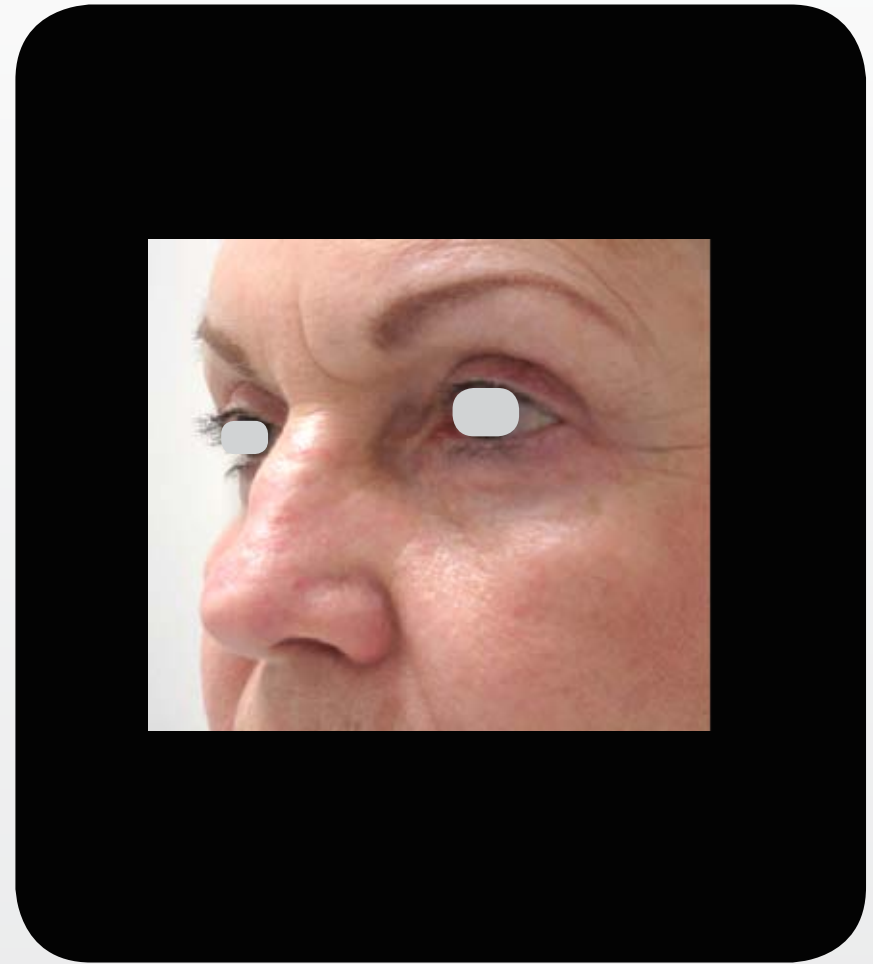

3 months after 1 treatment

Bleph™ - for Upper Eyelid Blepharoplasty, Combo™ for Lower Eyelid Resurfacing



Baseline

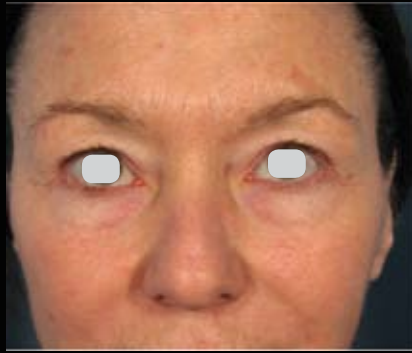

6 months after 1 treatment

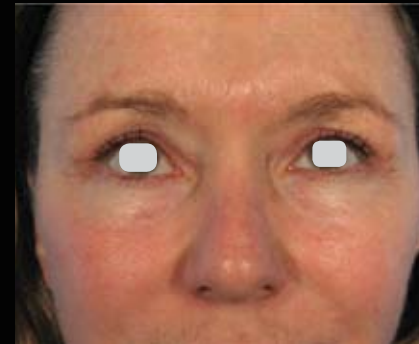Courtesy of Girish Munavalli, MD

PB-1002909 Rev D

Bleph™ - for Upper Eyelid Blepharoplasty

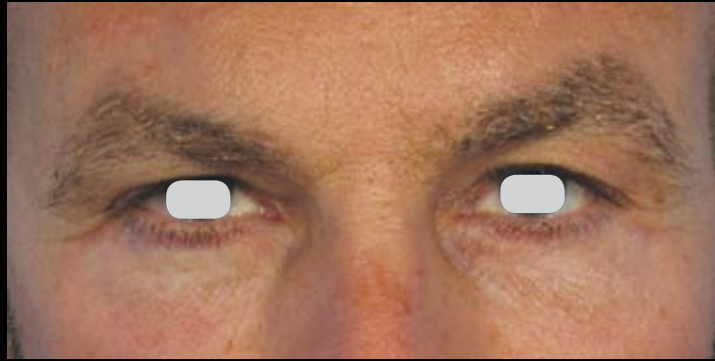

Baseline

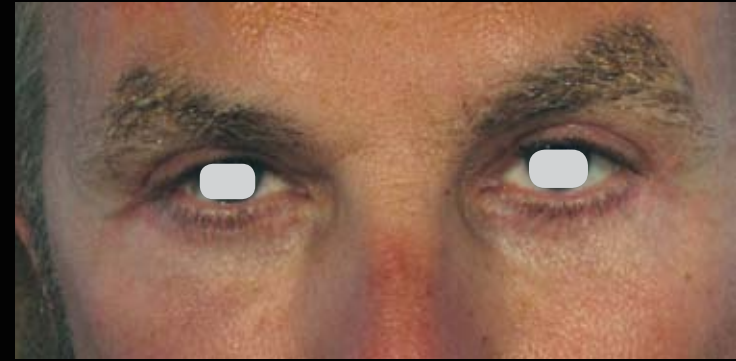

4 months after treatment

Bleph™ - for Upper Eyelid Blepharoplasty



Baseline

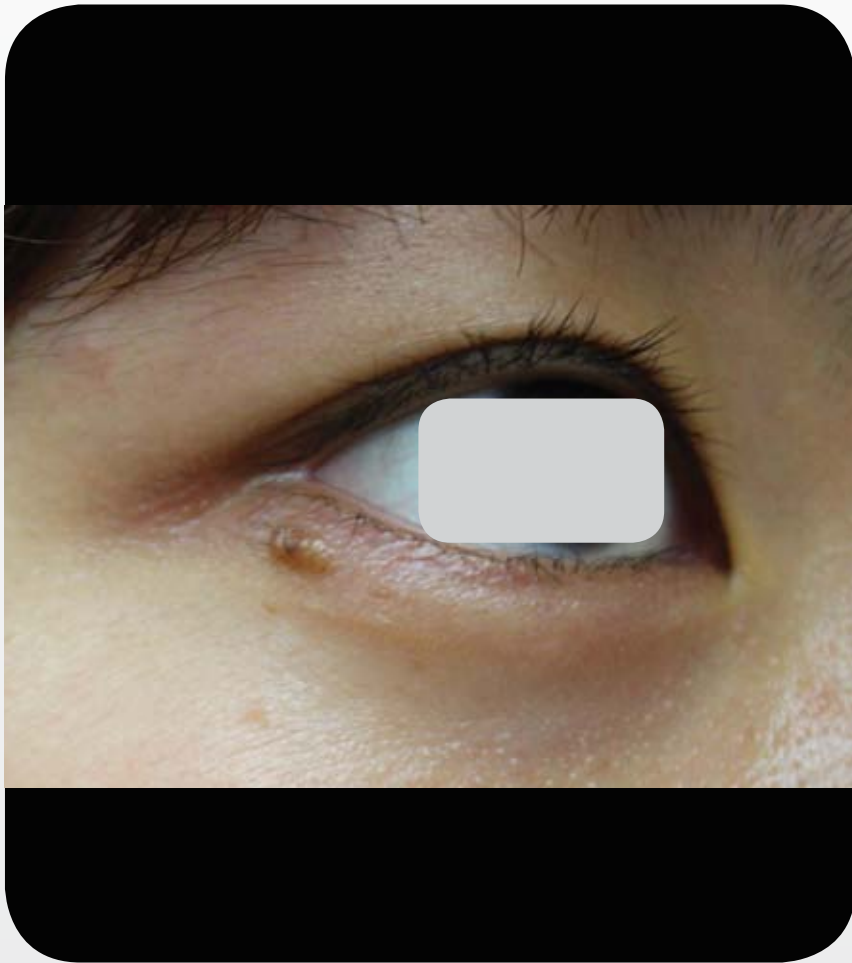


4 months after treatment


Courtesy of Girish Munavalli, MD

PB-1002909 Rev D

FineTouch™ - for Soft Tissue (Mole) Removal



Baseline

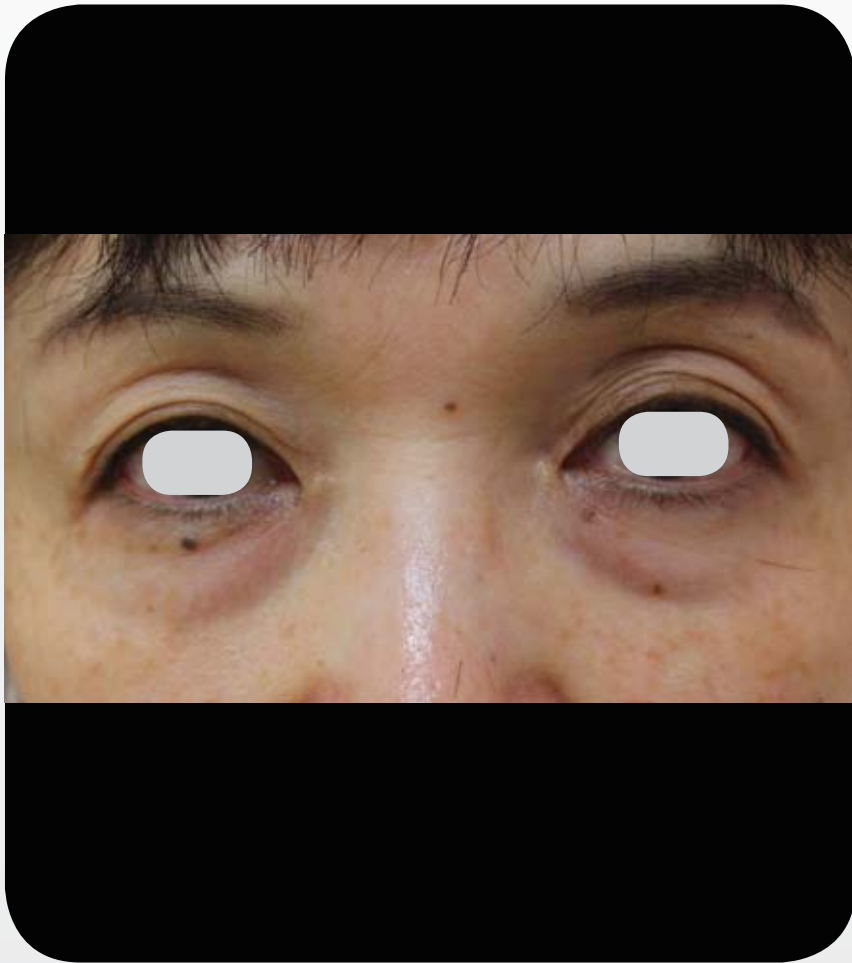


3 months after 1 treatment

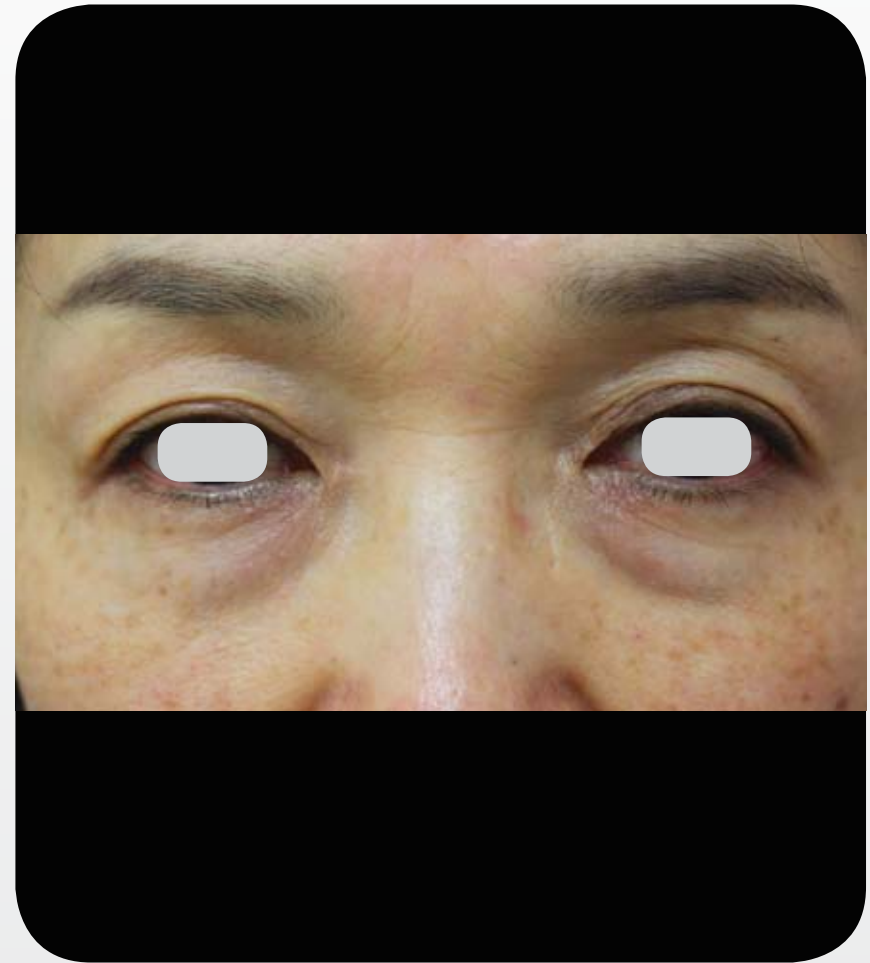Courtesy of Nariaki Miyata, MD

PB-1002909 Rev D

FineTouch™ - for Soft Tissue (Mole) Removal



Baseline

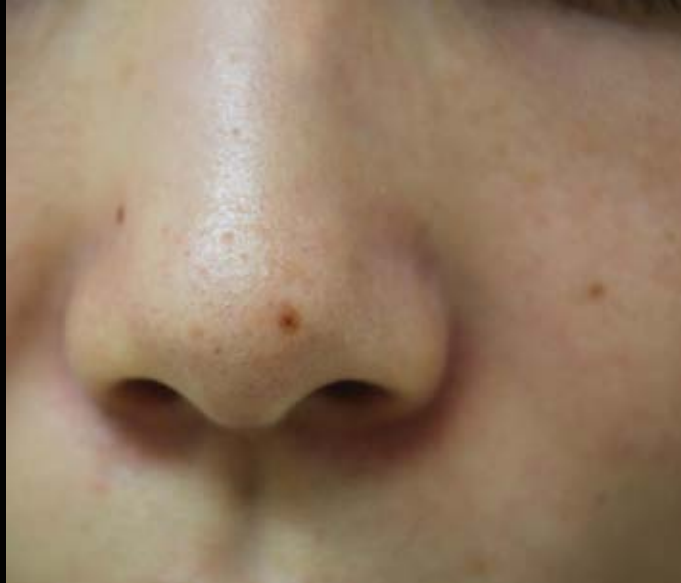

3 months after 1 treatment

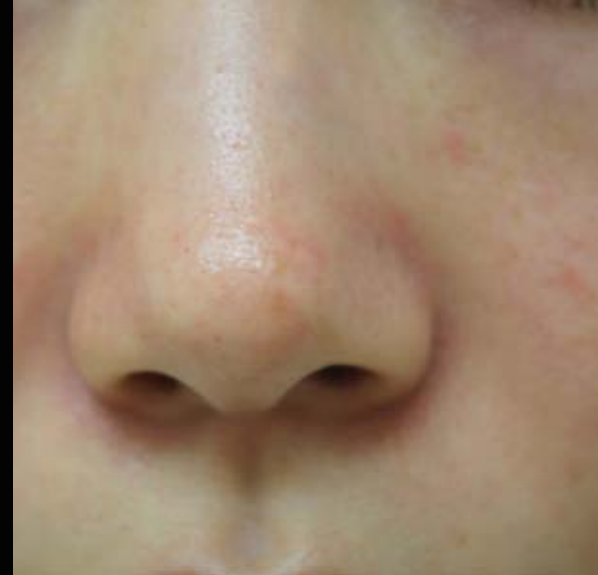Courtesy of Nariaki Miyata, MD

PB-1002909 Rev D

FineTouch™ - for Soft Tissue (Mole) Removal



Baseline

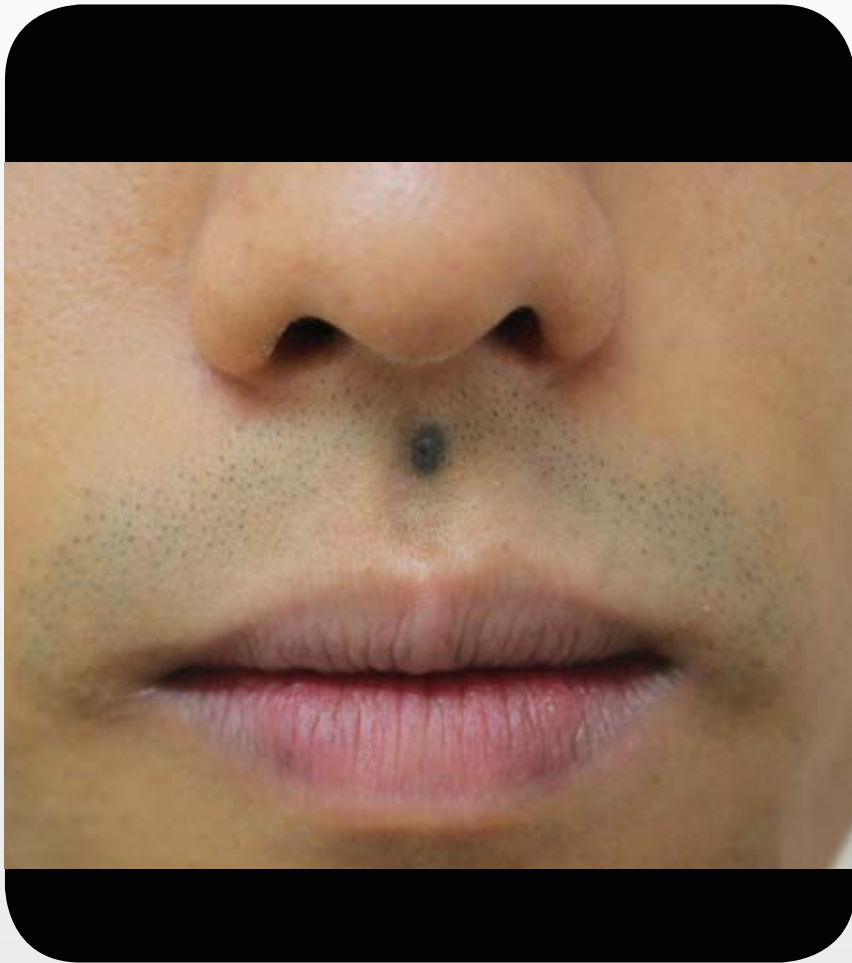

3 months after 1 treatment

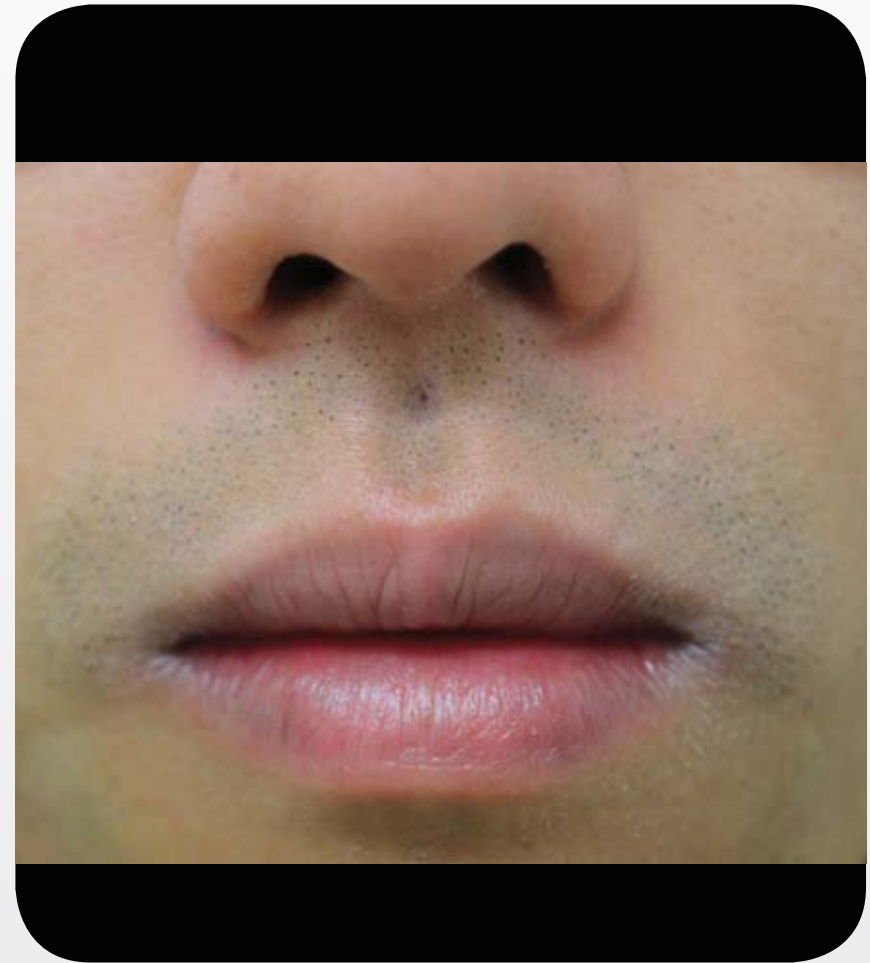
Courtesy of Nariaki Miyata, MD

PB-1002909 Rev D

FineTouch™ - for Soft Tissue (Mole) Removal



Baseline

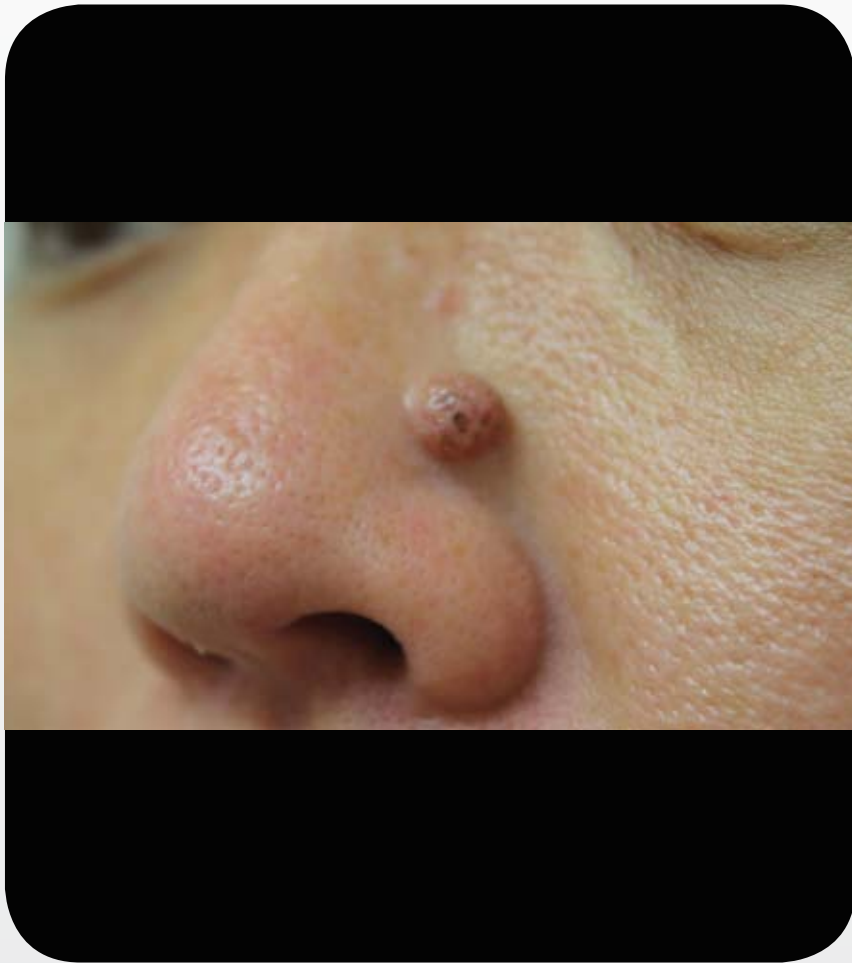

3 months after 1 treatment

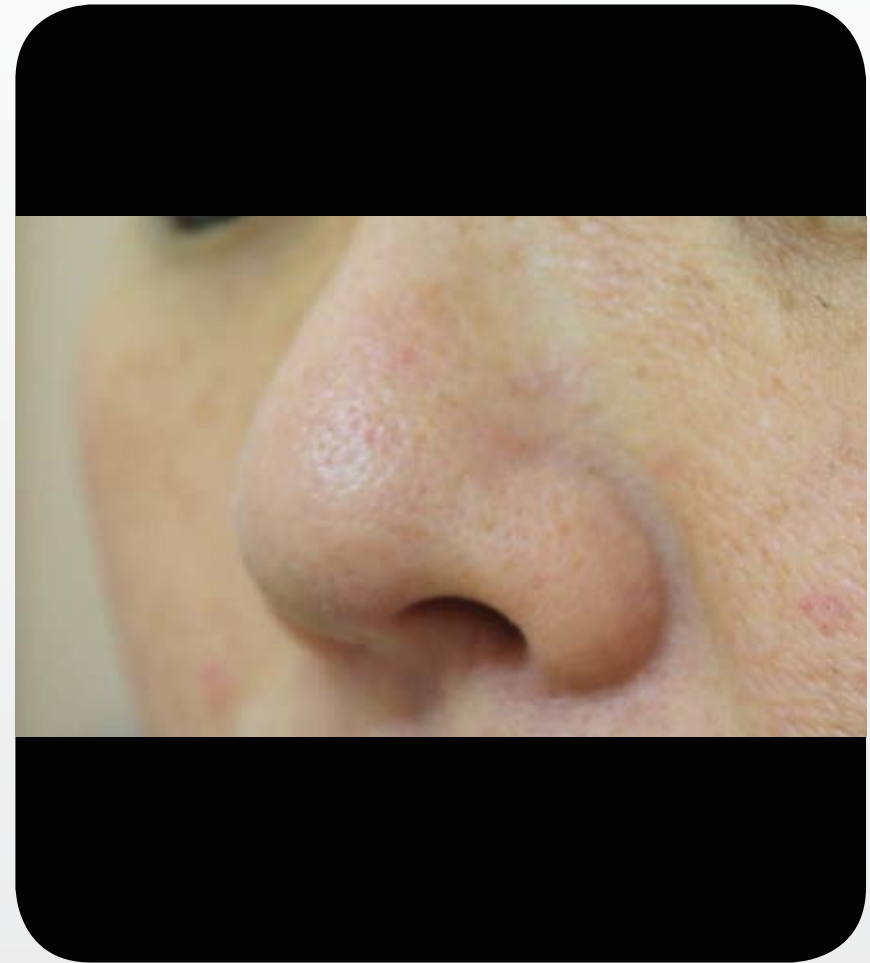
Courtesy of Nariaki Miyata, MD

PB-1002909 Rev D

FineTouch™ - for Soft Tissue (Mole) Removal



Baseline

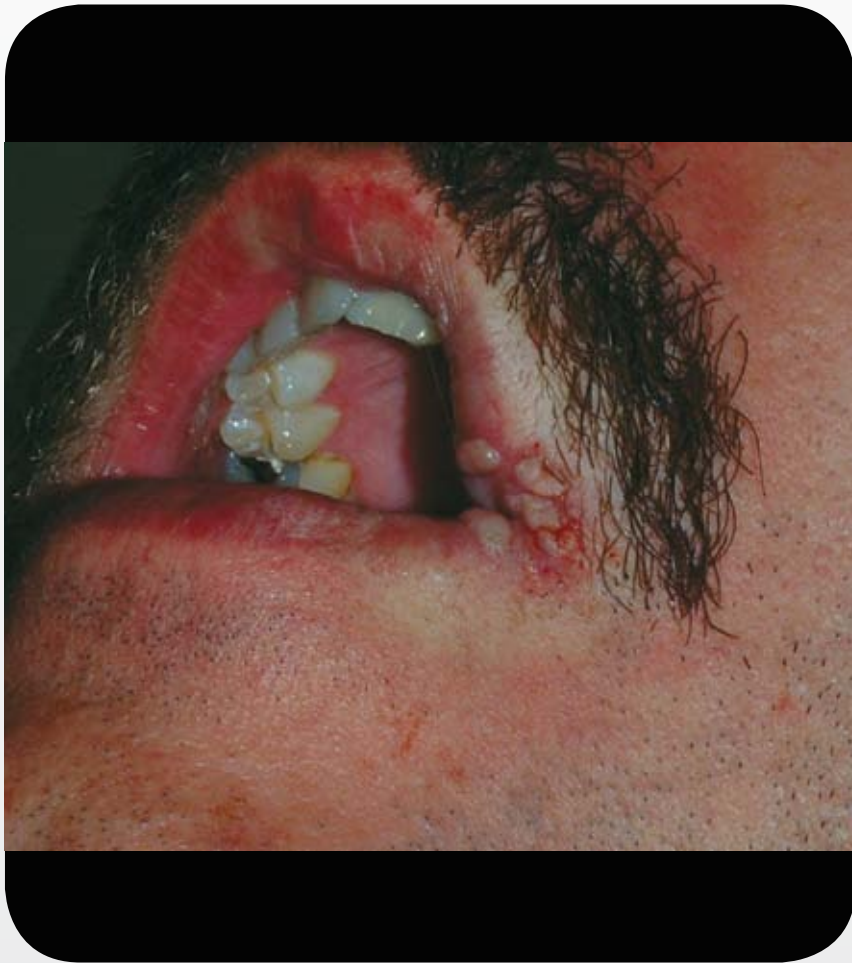

3 months after 1 treatment

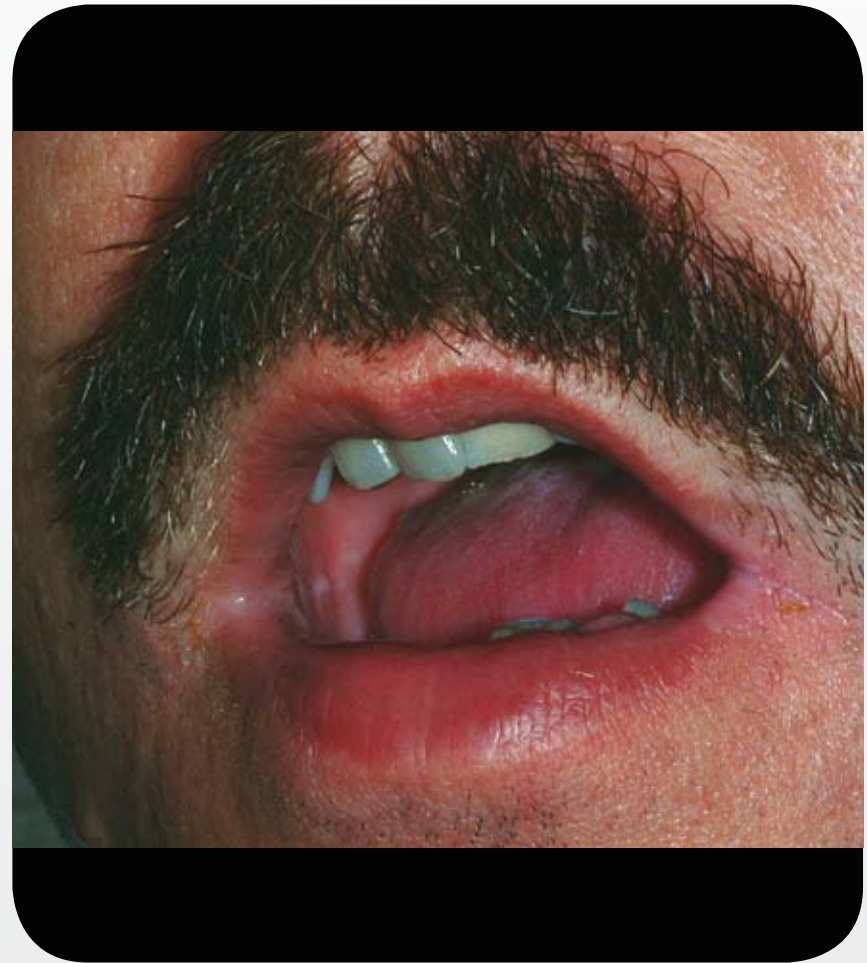
Courtesy of Nariaki Miyata, MD

PB-1002909 Rev D

Soft Tissue (Wart) Removal



Baseline



3 months after 1 treatment

Courtesy of E. Victor Ross, MD

PB-1002909 Rev D